

Broad Ligament Hematoma After Spontaneous Vaginal Delivery: A Case Report

Kashika¹, Harsha Gaikwad²

¹(Assistant Professor, Department Of Obstetrics and Gynaecology, Vardhman Mahavir Medical College & Safdarjang Hospital, New Delhi, India)

²(Professor, Department Of Obstetrics and Gynaecology, Vardhman Mahavir Medical College & Safdarjang Hospital, New Delhi, India)

Abstract : Broad ligament hematoma is a rare but dangerous complication that can occur following delivery. The incidence varies from 1 in 20,000 to 1 in 35,000 deliveries. It usually occurs following difficult and instrumental deliveries. It requires strong clinical suspicion to diagnose a case of broad ligament hematoma. The management varies from observation to surgical exploration. Here we present a case of broad ligament hematoma following a spontaneous vaginal delivery.

I. Introduction

A vaginal delivery can be associated with a number of complications. One such rare complication is a broad ligament hematoma. The incidence of broad ligament hematoma varies from 1 in 20,000 to 1 in 35,000¹. Broad ligament hematoma usually occurs due to a tear in cervix or upper vagina that extends to uterine or vaginal arteries. It is one of the dreaded complications which is life threatening and requires immediate attention and suspicion. Broad ligament hematomas have been usually reported following difficult traumatic or instrumental vaginal deliveries. We report a case of broad ligament and paravesical hematoma after a normal vaginal delivery.

II. Case Report

We present a case scenario of a patient who was brought to the emergency room in a poor general condition following spontaneous vaginal delivery conducted by midwife at a private hospital. The patient was para four and had one induced abortion. She had delivered about six hours before being brought to our hospital. There was no obvious history of prolongation of second stage of labor, precipitate labour or any instrumentation during delivery. Patient had delivered without any episiotomy but had excessive postpartum hemorrhage for which she had been managed medically with syntocinon drip and tablet misoprostol. Patient was referred to our hospital. She reached emergency room at 10.30 pm on 28.4.16 in shock with pulse rate of 116 per minute and blood pressure of 90/50 mm hg and respiratory rate of 24/min. was clinically very pale with hemoglobin of around 4 gm% . Her abdomen was distended with uterus around 24 weeks palpable and was well contracted and deviated to left side. On pervaginal examination, a right lateral wall vaginal tear was found and on bimanual palpation, a mass of around 9cm×6cm cm was palpable on right side of uterus in her right flank. Ultrasound guided paracentesis was done from the mass and frank blood was drained. Broad ligament hematoma was suspected. Adequate blood was arranged and patient was prepared for laparotomy. On laparotomy, a large broad ligament hematoma of around 9cm×6 cm was found. An incision was given on anterior leaf of the broad ligament and the hematoma was drained. A bleeding vessel was identified at the level 2 cm above internal os which was ligated. Right sided uterine artery was also ligated. Broad ligament tear was repaired. Right lateral vaginal wall tear was repaired vaginally. It was not found to be communicating with broad ligament tear. Post operatively patient was fine. She received multiple blood transfusions . Her vitals were stable. She was discharged on post op day 5.

[1]. Discussion

The most common complication of third stage of labour is postpartum hemorrhage². Though a rare entity, broad ligament hematoma should be suspected when a patient presents with sudden fall in hemoglobin post delivery without any evident post partum hemorrhage externally as was seen in our case barring the fact that she had an initial episode of post partum haemorrhage which was managed by uterotonics. The first line management includes resuscitation and volume replacement by crystalloids and blood transfusion under close monitoring. In case first line management fails, then surgical intervention may be required as was done in our case. Uterus sparing surgery should be tried in case bleeding vessel can be identified and ligated along with uterine artery ligation thereby achieving hemostasis³. In cases where it fails to control the bleeding then one may need to resort to hysterectomy as a life saving procedure. Thus, broad ligament hematoma even though a rare and

dreadful complication should always be kept in mind in cases which are non responsive to standard lines of treatment and where no obvious cause for shock is found by an obstetrician to prevent loss of life. This case has been presented for its rarity.

References

- [1]. Saleem N, Ali HS, Irfan A, Afzal B. Broad ligament hematoma following a vaginal delivery in primigravida. *Pak J Med Sci.* 2009;25:683-685
- [2]. Cunningham FG, Leveno KG, Bloom SL et al. *William's Obstetrics.* 24th edition. 2014
- [3]. Gilstrap LC, Cunningham FG, VanDorsten JP. *Operative Obstetrics.* 2nd Edition 2002.

IMAGE 1



Image 1. shows distension of lower abdomen due to hematoma

IMAGE 2

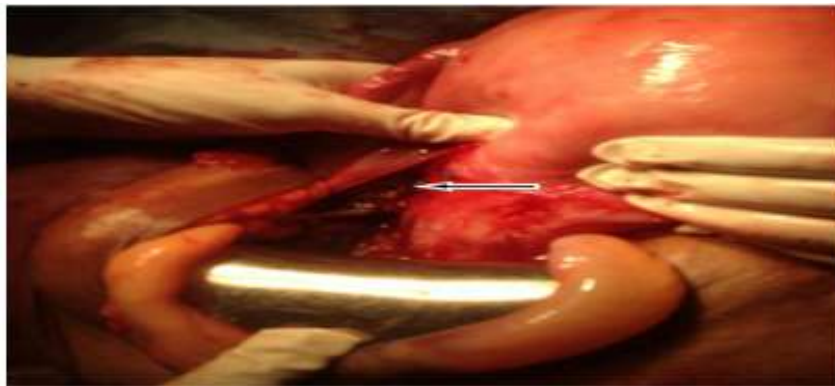


Image 2. shows broad ligament tear

IMAGE 3

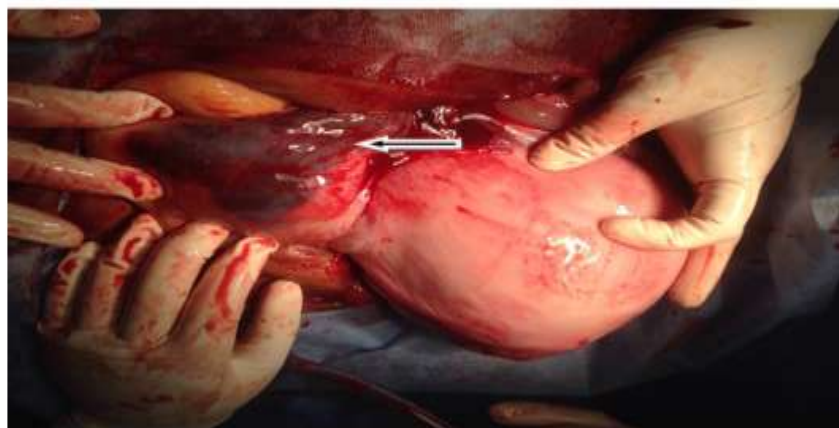

Image 3. shows paravesical hematoma